

Surgical Protocol

PECTUS EXCAVATUM

3D Custom-Made Implants technique



Prof Jean-Pierre Chavoin

Former head of Plastic Surgery Department of Toulouse University Hospital & ex-General Secretary of French Plastic Society (SOFCPRE) for 13 years then president

Expert in chest deformities treatment by custom-made implants with over 800 cases operated

PROTOCOL CONTENTS

| | |
|--|----|
| INTRODUCTION | 3 |
| PREREQUISITES | 3 |
| CT Scan of the Thorax | 3 |
| Thorax Photos | 3 |
| PRE-SURGERY | 4 |
| Measurement and marking | 4 |
| Preparation of the patient | 5 |
| Pre-surgery drawing | 5 |
| Surgical approach and incision | 5 |
| SURGERY | 6 |
| Incision | 6 |
| Dissection | 6 |
| Insertion | 8 |
| Suture | 9 |
| SPECIFIC CASES | 11 |
| Breast implants present before Pectus treatment | 11 |
| Breast implant after Pectus treatment | 11 |
| Secondary Pectus after Ravitch | 12 |
| Low lateral Pectus | 12 |
| Mixed Pectus (type 3 with lateral carinatum) | 12 |
| High costal protrusion on a low Pectus Arcuatum | 13 |
| Protrusion of the costal awning | 13 |
| SURGICAL OUTCOMES | 14 |
| BIBLIOGRAPHY | 15 |
| VIDEOS | 16 |
| Step by step surgery guide | 16 |
| Webinar 3D custom-made implant treatment of chest wall deformities | 16 |
| CONTACTS | 17 |

INTRODUCTION

Pectus Excavatum is the most common deformity of the thorax with between 1/300 to 1/1000 births per year worldwide. In most cases, this depression of the sternum doesn't have a functional impact, but often it leads to strong psychological complexes.

In the absence of cardio-respiratory symptoms, a filling surgery with 3D custom-made implant is the first-choice procedure. Indeed, it is a simple and unique surgery, with a low risk of complication, giving immediate results for all types of asymptomatic Pectus.

The technique is appropriate for both men and women aged from 15 to 60 with mild or severe pectus. It is particularly useful for asymmetric cases, low pectus arcuatum and revision after the failures of other techniques.

This very precise protocol is the result of an extensive experience of plastic, thoracic and pediatric surgeons, on hundreds of cases. Its objective is to avoid technical mistakes, to reduce the risk of complications, and to guarantee the best morphological and psychologic benefits.

PREREQUISITES

CT Scan of the Thorax

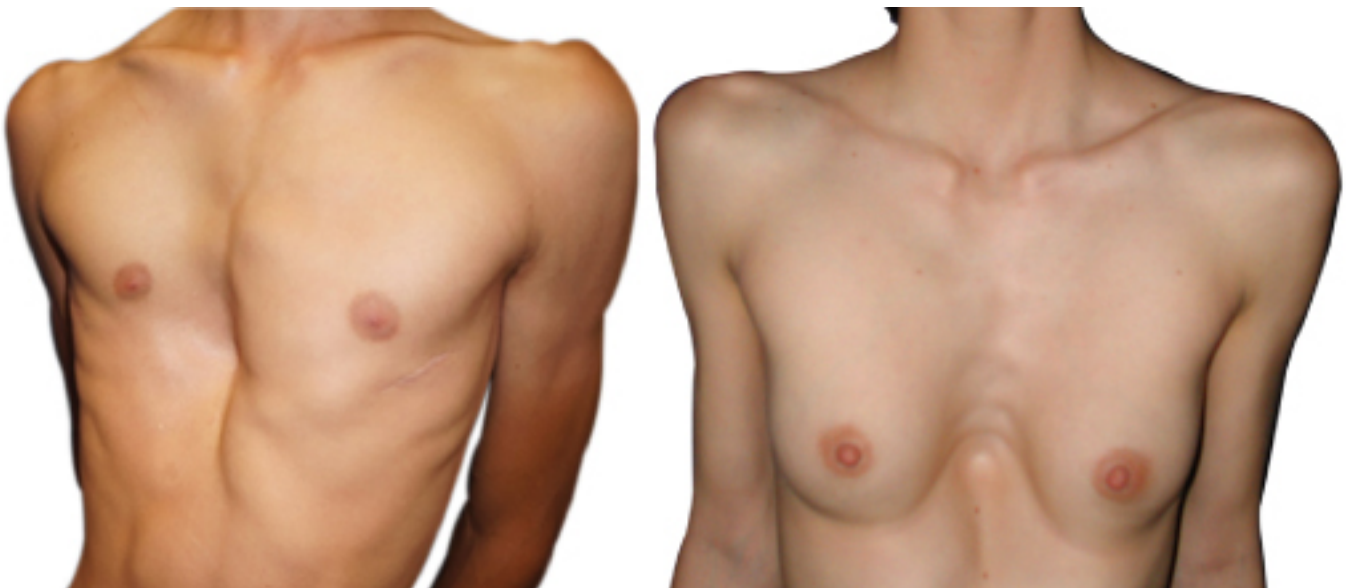Performed in a lying position, arms along the body (not in the usual elevated position).
Without contrast agent.

Thin slices of 1 to 1.2 mm comprising the whole thorax and abdomen.

Thorax Photos

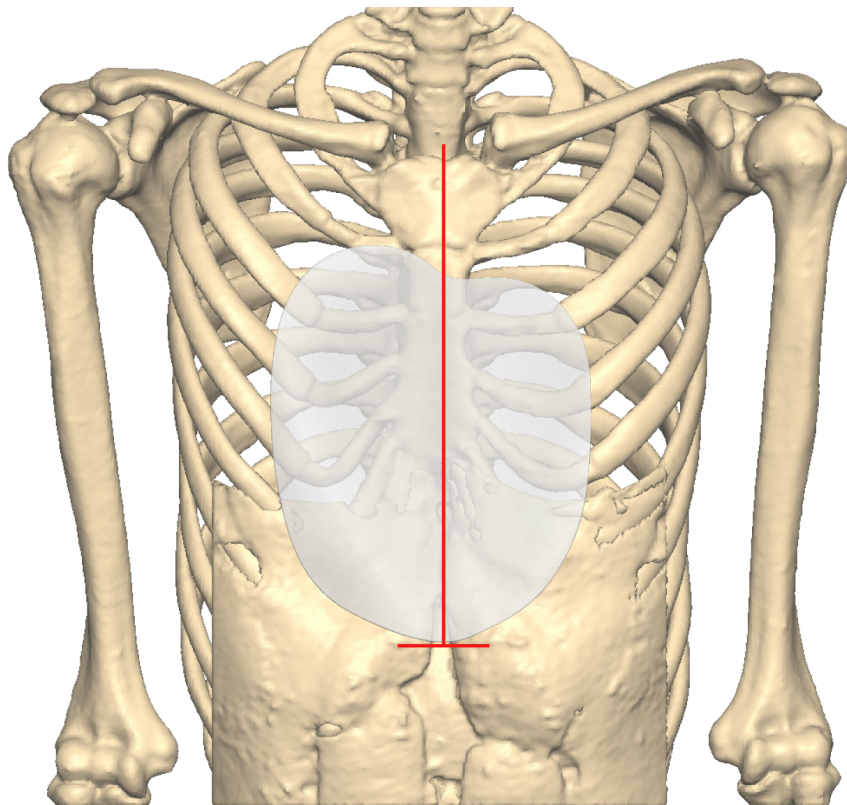
Photos of the patient's chest can be useful in addition to the scan data, especially for very muscular or overweight patients (e.g., adipomastia). These photos help to better take into account the external morphology of soft tissues, breasts, and fat distribution:

- Front face and ¾ angle photos: taken in a standing position, arms along the body, from the neck to iliac crests area,
- Lying position or low angle shot.



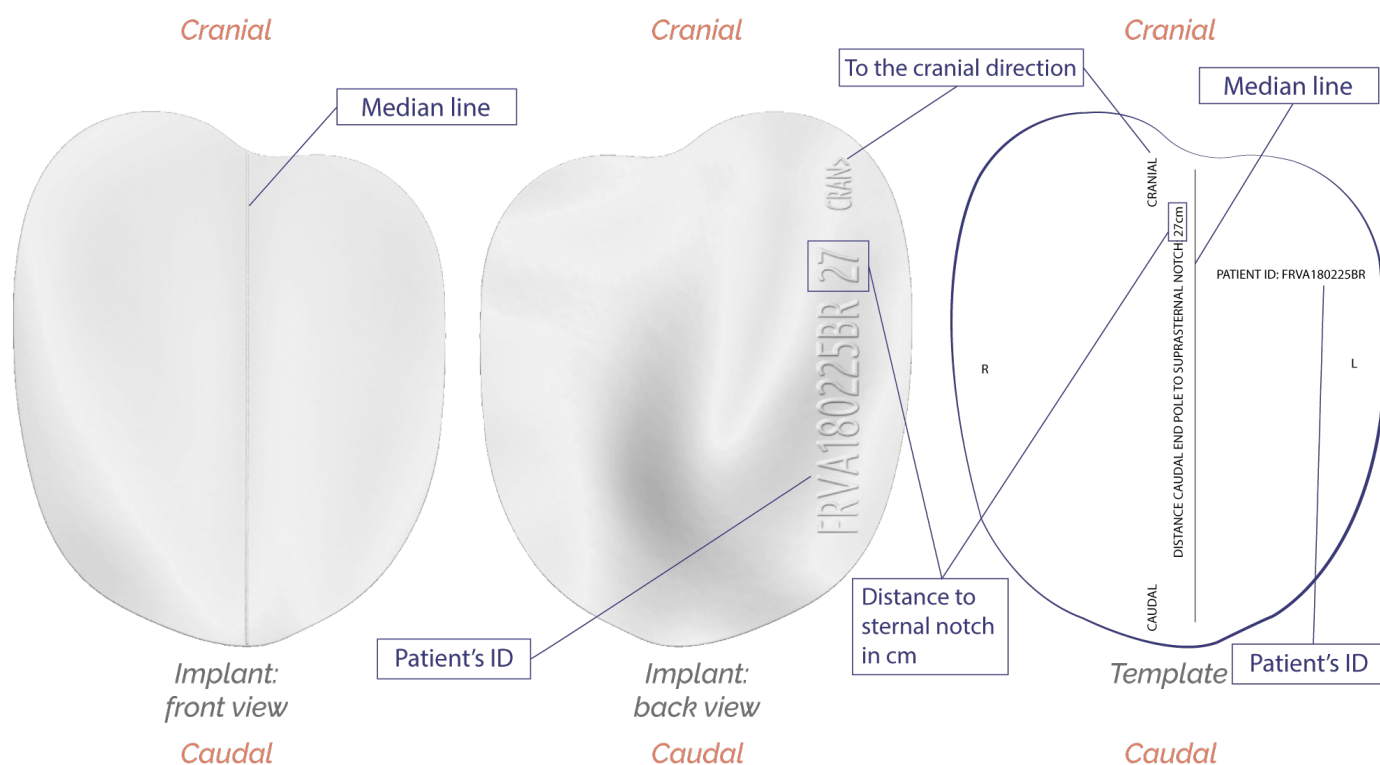
PRE-SURGERY

Measurement and marking



A transparent rigid template is supplied in the box in addition to the sterile implant. This template includes all necessary markings for preoperative drawing.

This measurement is the interclavicular to distal implant apex distance in cm taken on the virtual patient's chestwall. On the implant's and 2D template's front face, a median line represents the median proximal/distal sternum axis. With these two indications, the 2D template can be placed precisely in the correct position to trace around.



Preparation of the patient

- Traditional shower. scrub hands and feet. Nails should be short, clean and without nail polish.
- Shave with trimmer, limited to the pre-sternal area (10X15cm - dressing area).
- Dissuasive antibiotic infusion therapy with cefazoline 2G iv at the time of anesthesia induction, 30 minutes before the skin incision.

Pre-surgery drawing

Patient in supine position, arms along the body.

The precise implant's area is drawn with a permanent felt pen, using the non-sterile 2D template.

- Draw the pre-sternal midline from the supra sternal notch to the umbilicus,
- Mark the distance between the supra sternal notch and the apex of the implant (distance printed on the 2D template),
- The 2D template must be placed with the cranial side upwards and correctly oriented with Right (R) and Left (L) labels. The sternal line on its ventral side must align with the median sternal axis marked on the skin,
- Outline the position of the 2D template.

Antiseptic preparation, operating drapes, checkup, lighting control.

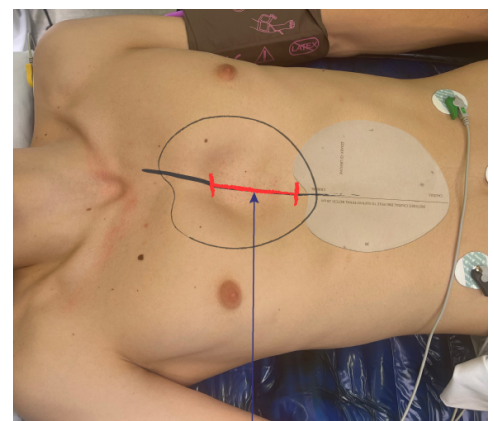
Surgical approach and incision

Good lighting is essential to visualize the entire dissection and hemostasis area through a limited approach: cold lighting is needed, either frontal or coupled with an illuminating retractor (9 cm Tebbetts retractor).



The incision line of 6 to 9 cm is a medial line, much more accurate than a horizontal lower one:

- Centrifugal dissection gives easier sight and control of the whole space, including the low sub-fascial one,
- Hemostasis is easier on large muscles' sections and on upper big perforating vessels (2nd and 3d intercostal space),
- Scar quality is improved by less suture tension in that area (skin excess, muscle suture), and by more efficient post-op compression on firm bone level than in a low approach.



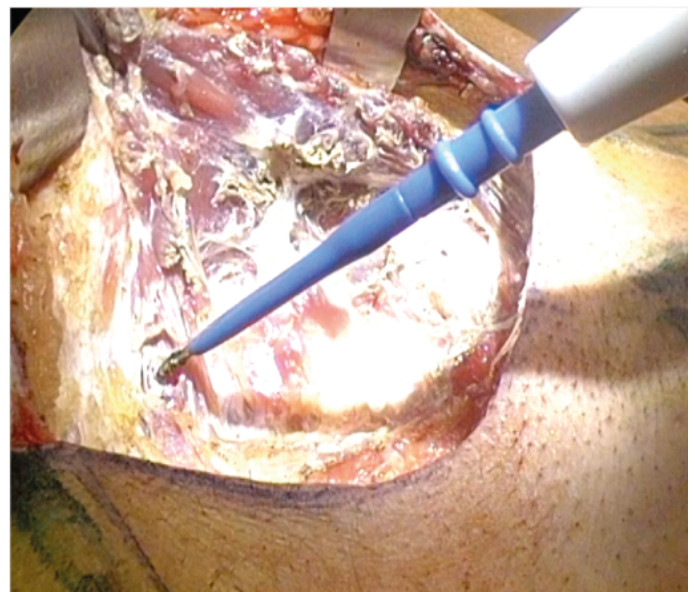
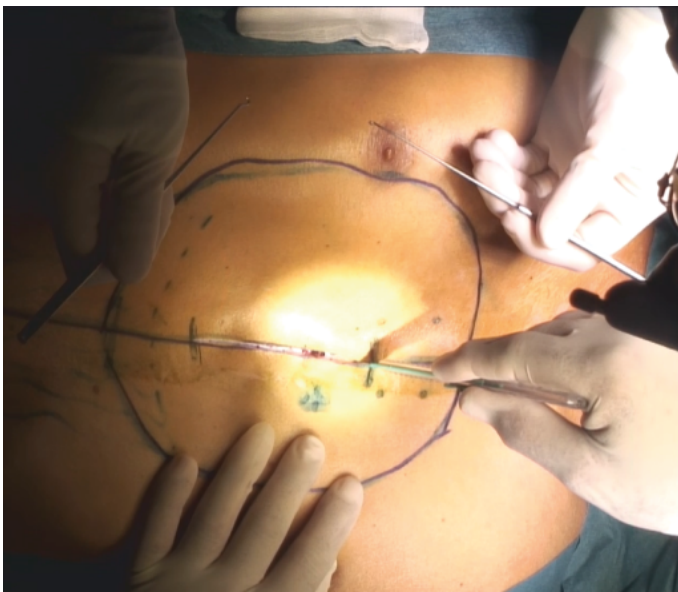
Drawing of the pre-sternal vertical incision (6-9cm)

Warning: The 2D template must be placed gently without pressure or distortion on the thoracic surface.

SURGERY

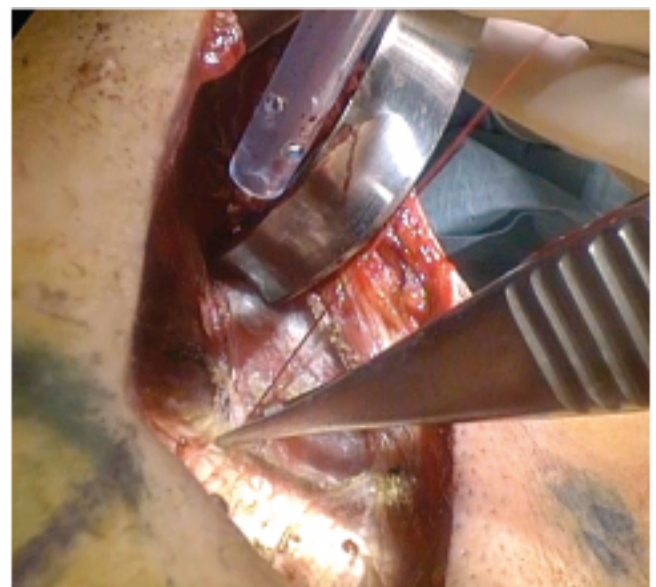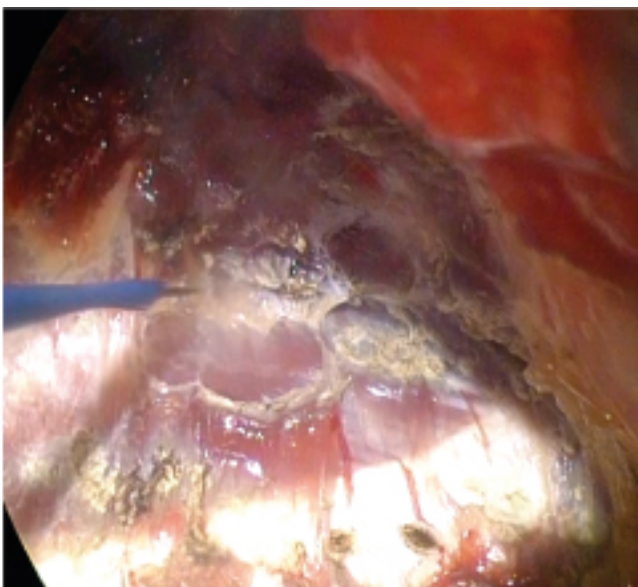
Incision

- Incision of the skin with scalpel blade without adrenaline infiltration,
- Assistant holds skin edges with two Gillies' hooks,
- Incision of the subcutaneous plan in section mode with the diathermy unit, protected short electrode (ideal: Stryker Colorado tips), to avoid burning of the skin edges.



Dissection

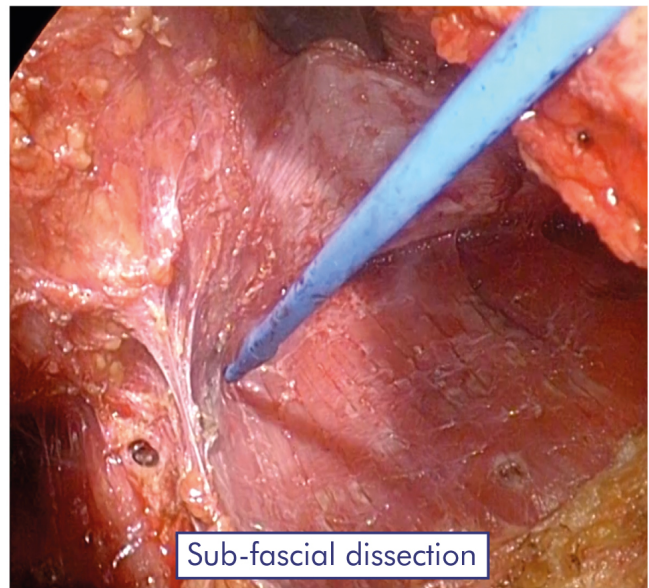
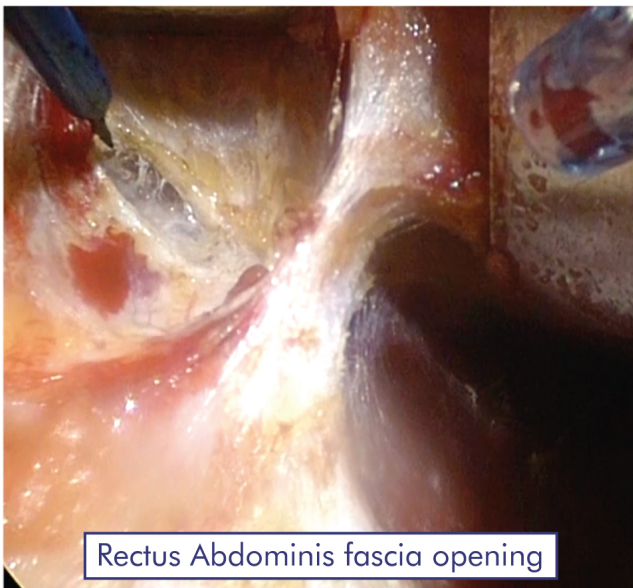
- On the pre-sternal plane, lateral undermining with section of sternal, costal and intercostal attachments of the Pectoralis Major (PM) over their entire medial and caudal insertions. The pectoralis minor muscle must be respected,
- The assistants stretch the muscle fibers using two Farabeuf or American retractors and pulling vertically, the muscle fibers must be cut 2mm above their costal and intercostal insertion,



- The dissection extends 1 cm beyond the limits of the area traced on the skin in order to prevent the fine edges of the implant from folding over, a potential risk in case of too short dissection,
- Hemostasis is performed precisely at each step,
- The assistant uses two larger retractors (Richardson, Ollier, Kalmorgen type, etc.) to facilitate distal dissection and hemostasis control under a Cold light illumination (frontal or on retractor),
- In the upper para-median part, the deep dissection plan is more difficult to respect: it is necessary to remain in the cellular plane under the Pectoralis Major and progress slowly to detect the large perforating vessels of the 2nd and 3rd intercostal spaces. If possible, they are coagulated before cutting them (mono or bipolar diathermy),

Warning: a trans-muscular cleavage would be hemorrhagic and make the undermining unclear: one must always remain in the clear precostal plane.

- In the caudal part, after section of the last lower and lateral insertions of the Pectoralis Major (PM), we reach the transition zone with the insertion of the Rectus Abdominis (RA) muscle,
- The fascia is opened high at the muscle insertion level with the diathermy unit in section mode, the muscle appears, the section is completed transversely from the lateral muscle edge to the median white line at least 5cm from the lower pole of the implant's tracing,



- The dissection continues in the plane located between muscle and fascia, retractors in vertical traction. Control of the perforating vessels is facilitated by the bipolar coagulation scissors. The limits are those drawn on the skin and the intermuscular septum must be respected on the white line.

Warning: be aware of the risk of peritoneal intrusion in case of a diastasis or secondary surgery after Ravitch procedure (inappropriate musculo-aponeurotic sections and resections).

- The surgeon checks the hemostasis, sets up large gauzes with hot saline in the detached area and then proceeds in the same way on the other side. At the end of this dissection, implant compartment's limits are checked:
 - The cranial detachment exceeds by 1cm approximately the limits traced on the skin,
 - In the caudal area, the two sub-fascial pockets are free and separated by the narrow septum on five centimeters.

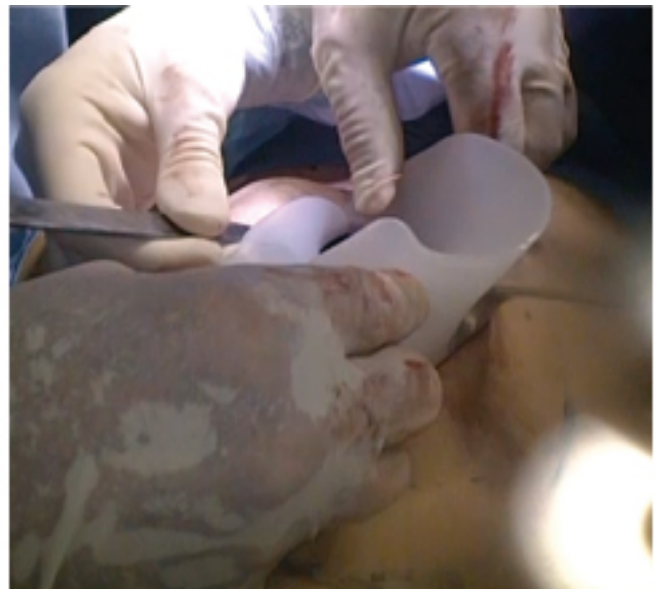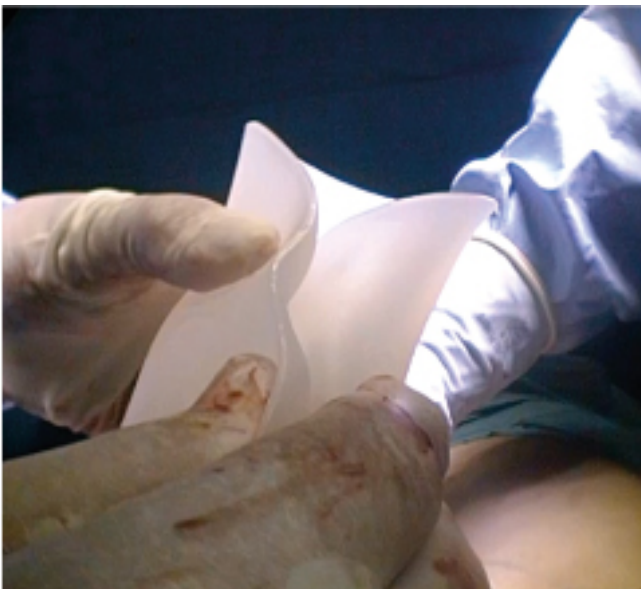- Final check of perfect hemostasis thanks to cold light lighting,
- In case of diffuse bleeding, insertion of large abdominal large gauzes soaked in hot saline (not lukewarm!): this accelerates primary coagulation (transformation of fibrinogen into fibrin).

Insertion

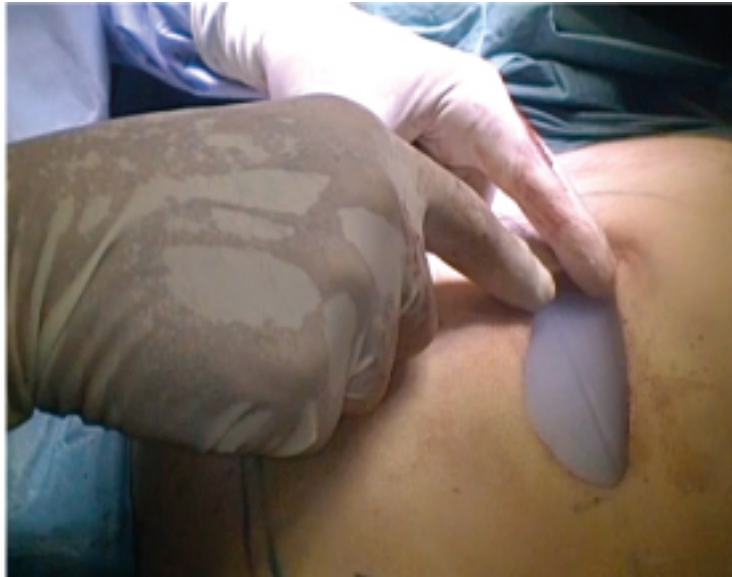- The surgeons change their gloves, the scrub nurse cleans the skin with serum, dries it, sets up clean border drapes and requests the implant,

The implant is delivered sterile in a double pouch: only the first is half-opened and presented to the scrub nurse who grabs the second sterile pocket containing the implant (in the event of an accidental fall, the implant could still be recovered sterile!).

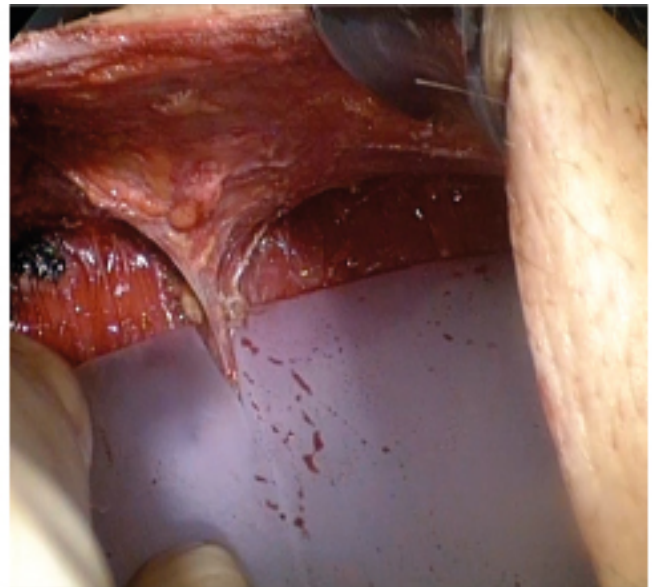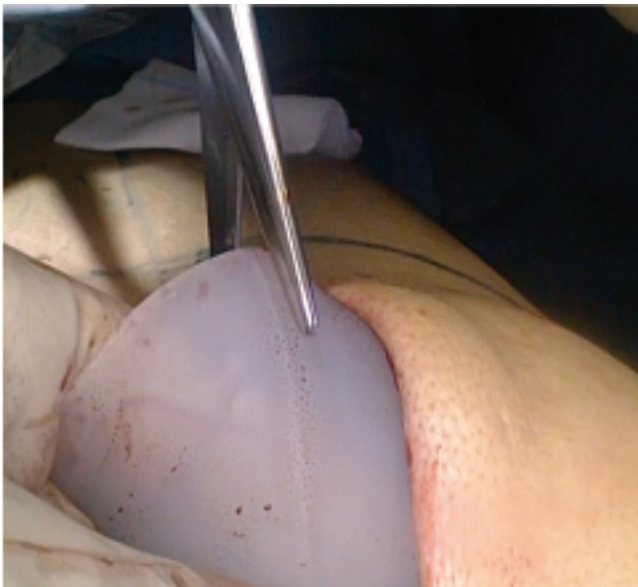- After changing gloves, the surgeon for one last time will check the whole cavity, its limits and of course completes the hemostasis if needed,
- The surgeon will then ask the scrub nurse to open the last pocket. He grabs the implant, folds it over its longest axis (usually vertical) and, supported by Farabeuf retractors, immediately introduces it into the cavity in the right position,



- The implant will spontaneously deploy and position itself within the cavity: the frontal vertical mid-sternal line appears in good position, otherwise the implant is moved into the right position,
- Once the implant is in place, its lower pole is externalized. In the absence of muscular diastasis, the surgeon cuts it on the line for 4-5 cm, using straight Mayo scissors. The surgeon inserts it under the fascia straddling intermuscular septum: the caudal part of the implant must be perfectly flat on the muscle plane: his fold would make it visible under the epigastric skin.



Note: if there is not enough medial space the implant medial section can be widened in a triangle shape. In case of complete diastasis of the rectus abdominis muscles with absence of septum, the implant is placed under the fascia, on the muscle without section.



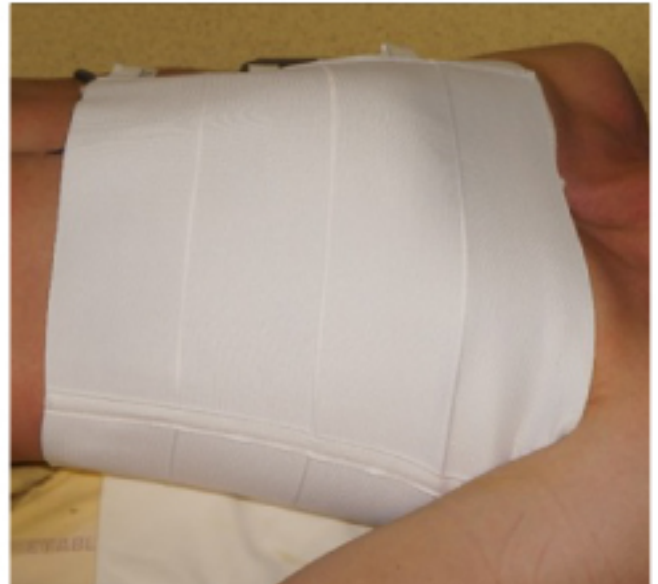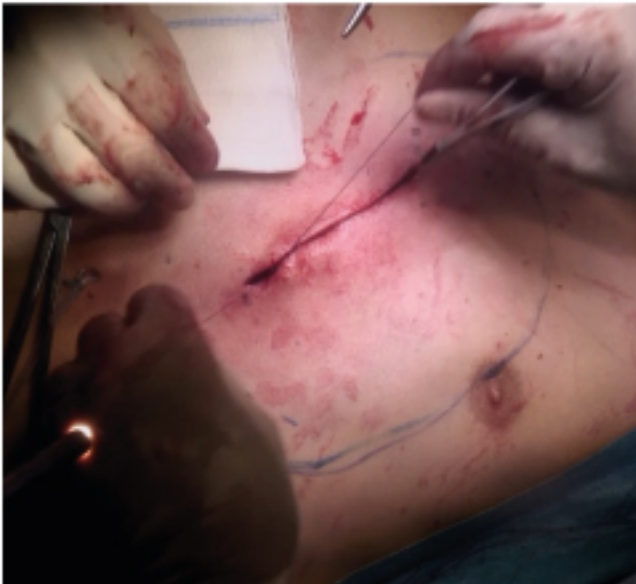Suture

- The two detached Pectoralis Major muscles are sutured together on top of the implant,

Warning: as sutured together, the forced contraction of the two pectoralis major could lead to a transverse movement visible under the skin. There is no functional discomfort or secondary atrophy, but patients practicing intensive weightlifting or bodybuilding must be informed.

- The muscular plane is sutured with Vicryl 0 large needle with separated inverted stitches from the cranial part to the caudal limit. If there is no more muscle distally, the last stitch will be based on the deep fascia. The knots are all in deep position, under the muscle,

Warning: no need of suction drainage whose huge depression between two smooth surfaces can cause hematoma by aspiration of big vessels coagulation's clots and favor a contamination by saprophytes.



- The subcutaneous plane is sutured with 5 inverted 3/0 monocryl stitches. Due to absence of tension, 4 or 5 knots short cut are enough: the knots remain deep, the strands must not appear towards the surface,

The use of absorbable braided Vicryl or Polysorb threads is not recommended for subcutaneous use, as they have a higher risk of picking up saprophytic germs from the skin, especially if numerous knots lead to the formation of a rigid «braid» which risks becoming direct outward-a real highway for saprophytic bacteria (anaerobic *Cutibacterium acnes*) or virulent bacteria (*Staphylococcus*).

- A dermal plane is done with a continuous suture with 3/0 monocryl: the thread must go in the deep dermis,

Warning: avoid too much superficial insertion as this could block the suture, create a «whitening» of the epidermal edges (signs of ischemia) and risk of a necrotic line occurrence.

- The continuous suture must slide well: it will be stopped by a single small knot at one end which will be inserted by a strong longitudinal traction. The thread is cut 3cm from its outlet and held by a steri-strip,
- The dressing is standard,
- A soft Dacron felt pad (Rolta) is placed on the pre-sternal area, then a loose compression is put: either a provisional elastic abdominal belt (Thuasne Cicatrex), or directly a thoracic vest (MedicalZ S033).

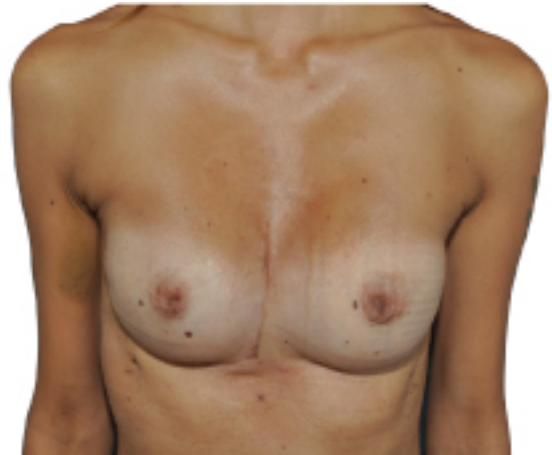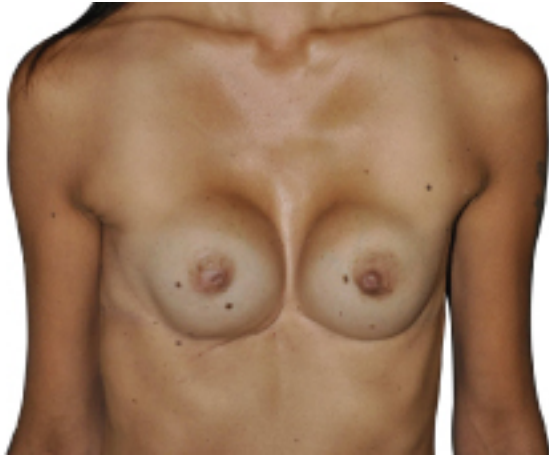Warning: a too strong circular compression is painful, however insufficient compression promotes seromas.

SPECIFIC CASES

Breast implants present before Pectus treatment

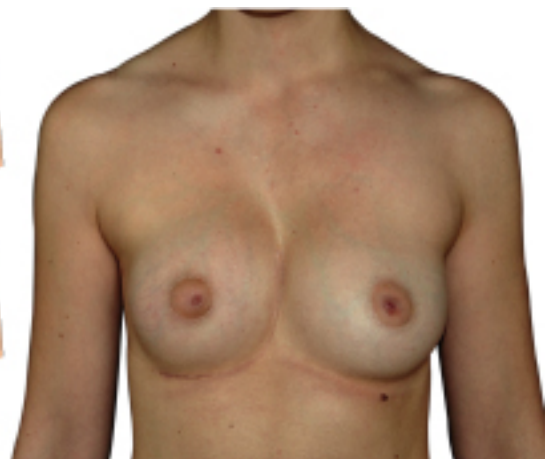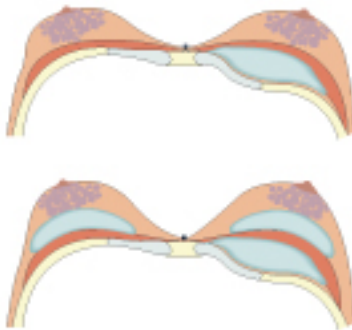
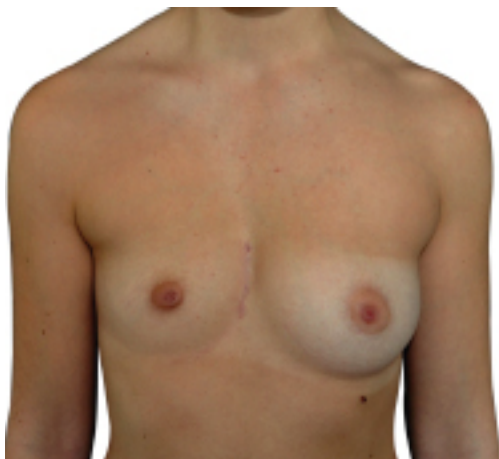If the breast implants are in the pre-muscular plane and away from the midline, it is possible to put the chest implant behind the muscle and keep the breast implants.

If not, they must be removed to prevent them from slipping in the middle and create a «symmastia».



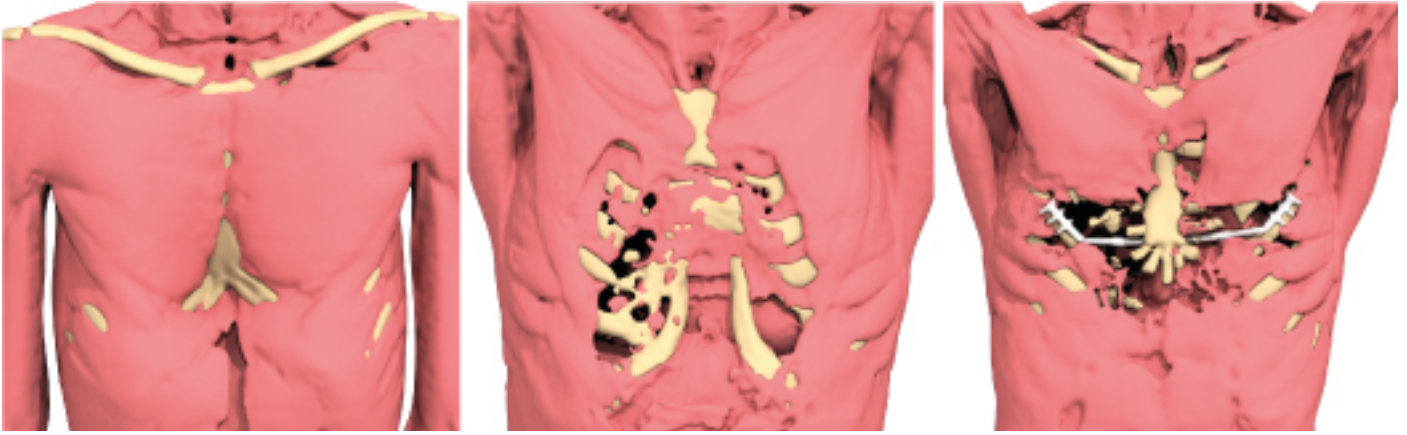Breast implant after Pectus treatment

In case of breast hypotrophy or asymmetry, it is possible to place breast implants, but always in a pre-muscular position and in a second operative step, 6 months after the treatment of the Pectus.



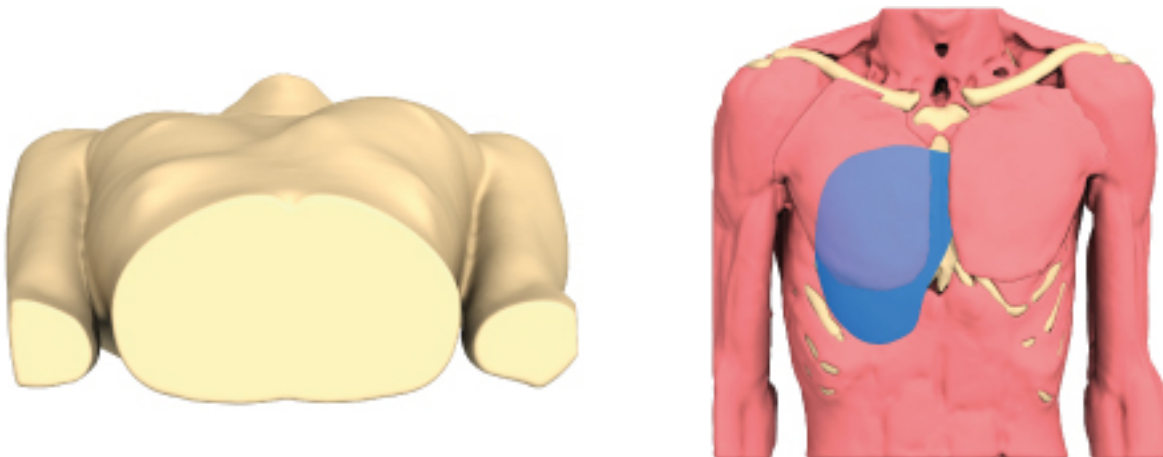
Secondary Pectus after Ravitch

In case of failure or insufficient results after a Ravitch-type remodeling sternochondroplasty, it is necessary to take into account the alteration and rearrangements of the muscular planes. Indeed, the strong retraction of the pectoral and abdominal muscles makes the dissection difficult, mostly at the abdominal level where the risk of peritoneal break-in may occur with a too deep dissection. In the absence of deep anatomical planes, the placement of a prior mesh may be required, similar to a hernia repair. This prevents caudal subcutaneous migration of the implant.



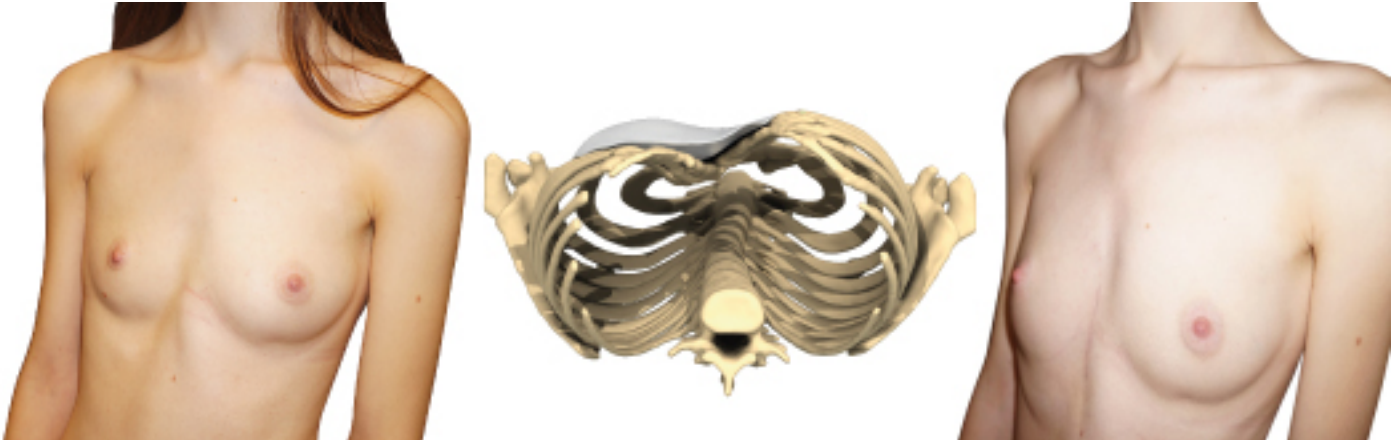
Low lateral Pectus

The Pectus extends laterally to the lower ribs. The dissection procedure is the same as normal cases: under the Pectorals Muscles. The lower dissection begins with the horizontal opening of the fascia, uncovering the plane of the Rectus Abdominis (RA) ipsilateral then continues laterally under the thin muscular plane of the external Obliquus Externalis (OE) to the limits drawn on the skin.



Mixed Pectus (type 3 with lateral carinatum)

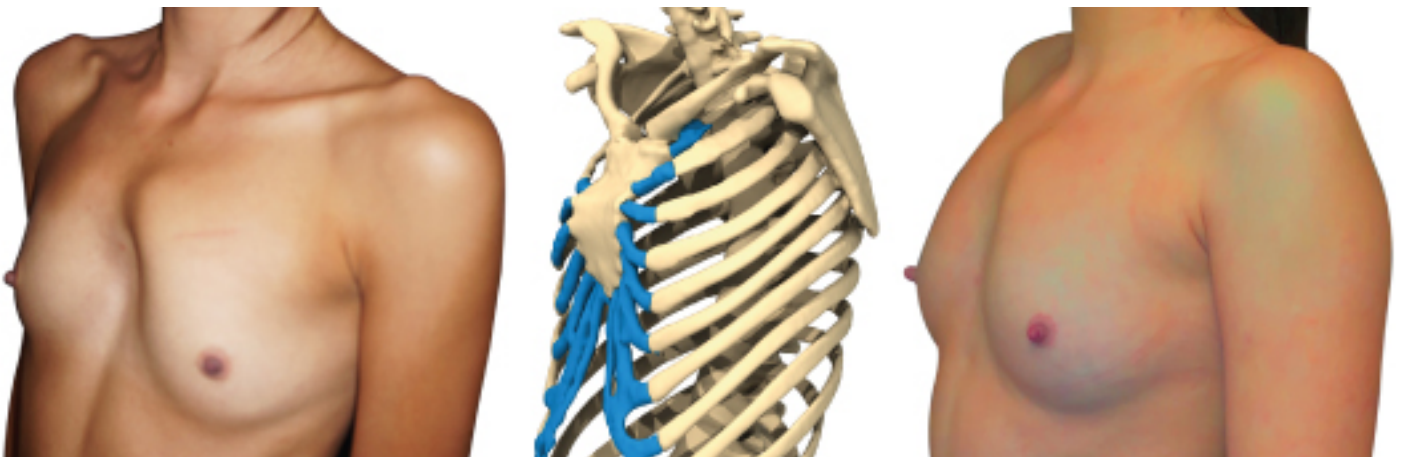Pectus Excavatum is associated with a lateral Carinatum ridge on the opposite side. The design of the implant must come up to the ridge while filling the Pectus. It is essential to detach both pectoralis major muscles although the unilateral depression.



It is very effective on women whose breast covers the malformation, but also on men particularly after the failure of another technique.

High costal protrusion on a low Pectus Arcuatum

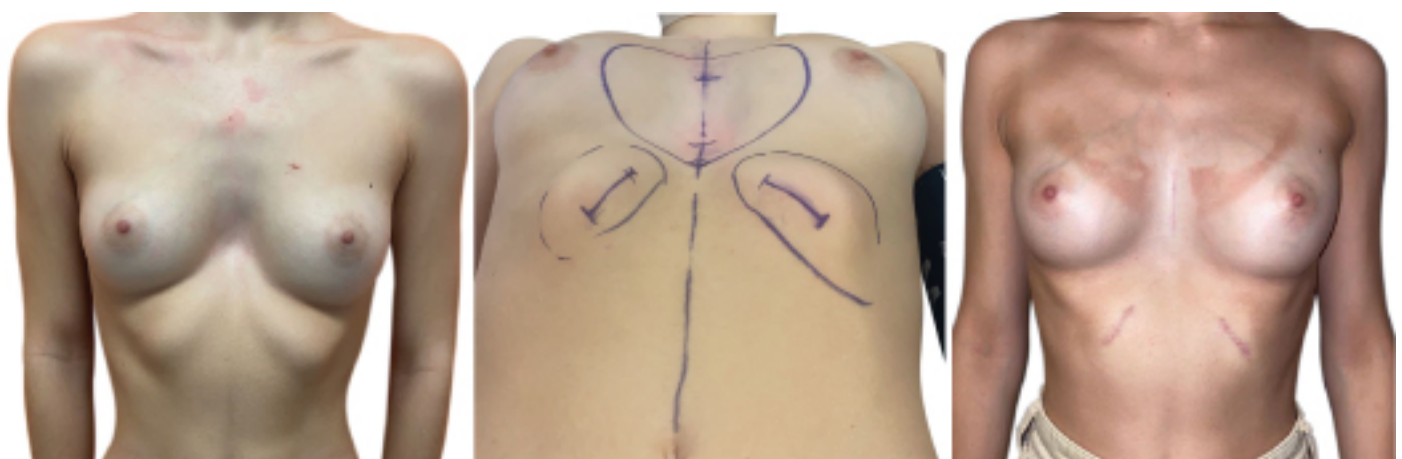Low Pectus Arcuatum may be associated with a high medial protrusion of costal cartilages. It is easy, by the classical approach, with a higher dissection, to free the cartilages and to level off with a diathermy its prominent medial part on each side.



Protrusion of the costal awning

The pectus is associated with a protrusion of the costal awnings. We can first dissect then resect a segment of costal cartilage.

Through a direct approach, a segment of rib cartilage is dissected, resected and the edges sutured.



SURGICAL OUTCOMES

- D+1: Checkup.

First puncture in the lower area, body upright or better, half seated in bed, in case of a vagal discomfort. The puncture is aseptic, this is made with a 19 gauge needle and one or several 60cc luer-lock syringes. Puncture should be made in the low declining zone, right or left median line, under the end of the scar. It gets 40 to 400cc of sero haematic collection.

- D+2: Checkup.

New puncture: the liquid is less haematic. The basic dressing is changed to a hydro-colloid Mepilex border EM 9x15 Monlyncke dressing. The dressing will be maintained for 8 days without being changed (no home-care nursing), it allows the patient to take a shower without being changed.

- D+2:

Thoracic jacket is put for 1 month 24/7 with a medial soft pad.



References:

- for men: Z Pectus belt - foam option (Medical Z)
- for women: ZBRA S021 bra with triangular foam pad

- D+8: Control consultation.

Dressing removing. Seroma's puncture if necessary in the lower area, body upright or half seated.

- D+15: Control consultation.

Dressing removal. Puncture in the lower area, body upright or half seated in bed if necessary: the liquid is clearer or serous.

- D+22: Control consultation.

Puncture in the lower area if necessary, body upright or half seated in bed. If the liquid is citrus and in small quantity, controls and punctures can be stopped.

Follow-up at **M3** (authorization for a progressive resumption of sports activity)

The complete and solid healing of the suture of the two pectoralis major muscles between them takes a year. The practice of sport is forbidden for at least **3 months** and must be resumed in a progressive and non-violent way for **one year**. Sports involving sudden movements of the

pectoral muscles, are not recommended for one year (push-ups, core-strengthening exercises, climbing, tennis, golf, contact sports, etc.).

SILICONE ELASTOMER PROPERTIES

The implant is made from a medical grade silicone elastomer and chosen according to its firm consistency in the medial part, high flexibility laterally and ending in «airplane wing».

The introduction via a short approach is made easier by the possibility of folding it. In the deep position under the musculo-aponeurotic plane, the edges are not visible and the implant totally stable.

This material is a foreign body, there is no immune «rejection» reaction, but a classic fibrous encapsulation which is an «exclusion» reaction and prevent the risk of contamination by blood and migration of the implant.

It is a solid rubber silicone elastomer: there is no risk of tearing, perforation or rupture, even in the long term. There is never any fibrous retraction (shell).

The implant has a smooth surface. Therefore, the long-term development of anaplastic large-cell lymphoma, recently described for some macro-textured breast implants, has not been reported to date.

Unlike breast implants filled with silicone gel, these implants can be kept for life.

Three silicone elastomer durometers are available. AnatomikModeling selects the appropriate softness depending on the indication, volume, and desired projection. For Pectus Excavatum, "Extra Soft" is generally used.

BIBLIOGRAPHY

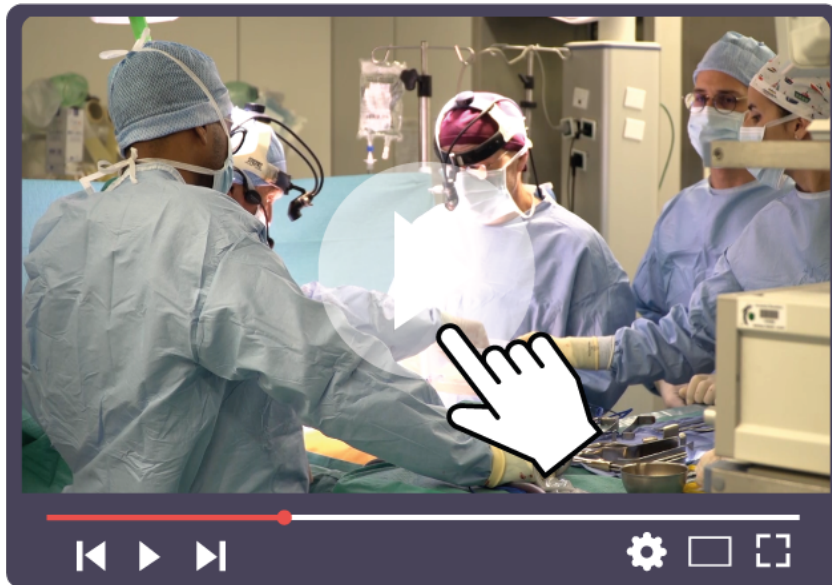Chavoin J-P, Grolleau J-L, Moreno B, Brunello J, André A, Dahan M, et al. **Correction of Pectus Excavatum by Custom-Made Silicone Implants: Contribution of Computer-Aided Design Reconstruction. A 20-Year Experience and 401 Cases.** *Plast Reconstr Surg.* 2016 May;137(5):860e–71e

Chavoin J-P, editor. **Pectus Excavatum and Poland Syndrome Surgery: Custom-Made Silicone Implants by Computer Aided Design.** Springer International Publishing; 2019 [cited 2019 Apr 24]

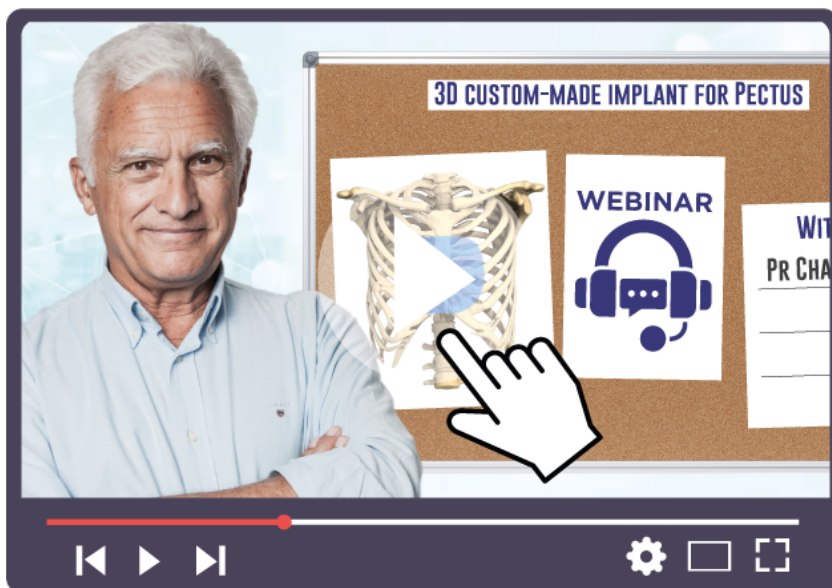Jean-Pierre Chavoin, MD, PhD, Flavio Facchini, MD, Akshay J. Patel, MA(Cantab), MRCS, and Ian Hunt, MD, FRCS(CTh). **The Role of Computer-Aided Design Implant Insertion in Revision Pectus Surgery.** *Ann Thorac Surg* 2021;112:e387-90

VIDEOS

Step by step surgery guide (bit.ly/3D-Implant-Operation-Tenon)



Webinar 3D custom-made implant treatment of chest wall deformities (bit.ly/Webinar-3D-Implant-Pr-Chavoin)



CONTACTS



Pr Jean-Pierre Chavoin

jean-pierre.chavoin@orange.fr



Design:

AnatomikModeling

7 bis rue des Capucines,
31320 Castanet-Tolosan

contact@anatomikmodeling.com

+33 (0)5 62 83 31 04

www.anatomikmodeling.com